

Coincidental Finding of Twin Dentigerous Cyst in an Achondroplasia Patient

MAMMOOTY IMTHY KELOTH¹, ABDUL AKBAR², LAXMIKANTH CHATRA³,
VAGISH KUMAR L SHANBHAG⁴, PRASHANTH SHENAI⁵

Keywords: Cone beam computed tomography, Fibroblast growth factor, Orthopantomogram

Dear Editor,

Achondroplasia is a nonlethal, commonly occurring skeletal dysplasia that affects more than 2,50,000 people worldwide [1]. This autosomal dominant disorder results from mutation in the Fibroblast Growth Factor Receptor 3 (FGFR3) gene. The disease has an expression rate of 100%. Patients commonly exhibit frontal bossing, midface hypoplasia, brachycephaly, short limbs, short stature and muscular hypotonia [2]. Thorough literature review reveals that only one case has been published in PubMed database regarding the coincidental findings of occurrence of dentigerous cyst in an achondroplasia patient [3]. That case occurred in a male child patient of eight year old. Here, we describe a case of coincidental finding of multiple dentigerous cyst in an adult patient.

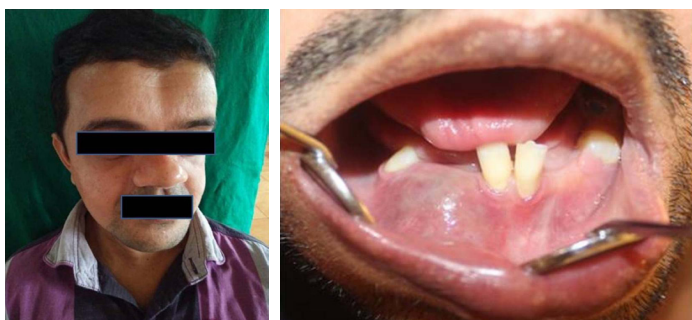
A 35-year-old male patient visited our department with a chief complaint of swelling on right lower front region of mouth since one month. The patient gave history of painless slow growing swelling which was initially small in size and attained the present size during the course of past one month. It was associated with mild difficulty in mastication. No history of bleeding or pus discharge from the swelling was noticed. There was no history of numbness or any trauma in that region. Patient also gave history of over-retained deciduous teeth which was uneventfully extracted and most of the permanent successors had not yet erupted.

On general physical examination, patient exhibited features of stunted growth and dwarfism with disproportionate shortening of the proximal limbs, short fingers and toes, large head with prominent forehead, frontal bossing with a medial depression on the frontal bone and small midface with a flattened nasal bridge [Table/Fig-1]. On intraoral examination, there was localized well defined swelling measuring about 3X2 cm on labial aspect of teeth# 42, 43 region, extending from the edentulous space of teeth# 42,43 to the floor of the labial vestibule, causing obliteration of labial vestibule [Table/Fig-2]. Colour of the overlying mucosa appeared mildly erythematous and surface over the swelling appeared smooth and non-ulcerated. On palpation, swelling was found to be soft in consistency, fluctuant, non-tender, immobile and fixed to the underlying structures. There was no bleeding or pus discharge elicited during palpation. Hard tissue examination revealed several

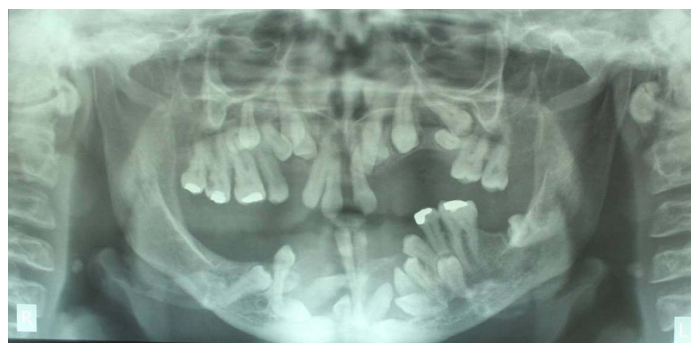missing teeth in both arches. Grade II mobility was exhibited by teeth# 41 and 31. On aspiration, brownish red cystic aspirate was obtained and sent for cytological examination. Based on the history and clinical examination provisional diagnosis of dentigerous cyst in relation to tooth# 43 was arrived. Differential diagnosis included unicystic ameloblastoma and central giant cell granuloma.

Orthopantomogram(OPG) showed multiple impacted supernumerary teeth in the mandibular and maxillary jaws. Mandibular arch shows two ill-defined radiolucencies in the parasymphiseal region, one which is arising from the distal aspect of tooth# 31 and the other one from the distal aspect of tooth# 41, approximately one cm away from midline [Table/Fig-3]. Both radiolucencies extended up to the premolar region. Both the radiolucencies are associated with multiple impacted supernumerary teeth of variable morphology. Lower border of the mandible in the area of radiolucencies appeared intact. CBCT was taken with large Field of View (FOV). In the maxillary arch, multiple impacted teeth of varying morphology was noted on both right and left quadrant. In mandibular arch, two well-defined radiolucencies with non sclerotic margin each of size 1.5 x 2 cm was noted in the anterior mandibular region distal to teeth# 31 and 41. The radiolucency on the right side extended from the distal aspect of tooth# 41 till the first premolar region and was associated with five impacted teeth all of which were within the radiolucency. The lesion on the left side extended from the distal aspect of tooth# 31 till the first premolar region and was also associated with five impacted teeth all of which were within the radiolucency. Internal structure of both radiolucencies appeared to be of mixed radiodensity. The radiolucency on the right quadrant appeared to cause expansion and thinning of lingual cortical plate and perforate the buccal cortical plate. The radiolucency on the left quadrant caused minimal buccolingual expansion. Lower border of the mandible appears to be intact. Around 1.5 to 2 mm depth of bone was available from the lower end of the lesions till the inferior border of the mandible [Table/Fig-4,5]. Radiograph impression was that of two dentigerous cysts, one each on right and left parasymphiseal region.

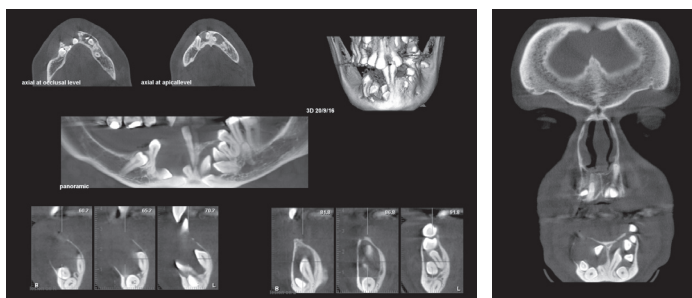
The lesions were enucleated along with removal of impacted teeth followed by reconstruction with recon plate. The biopsy of



[Table/Fig-1]: Extraoral examination. **[Table/Fig-2]:** Intraoral examination.



[Table/Fig-3]: Orthopantomogram shows multiple impacted teeth with associated two ill defined radiolucencies in parasymphiseal region of mandibular arch.



[Table/Fig-4]: Conebeam computed tomograph showing various sections including axial and panoramic view. **[Table/Fig-5]:** Conebeam computed tomograph showing coronal section.

the surgical specimens revealed cystic lining of non-keratinized stratified epithelium of 2 to 3 layers thickness. Focal areas of the lining showed epithelial hyperplasia and few mucous cells. Capsule with densely parallel arranged collagen fibers showed the presence of chronic inflammatory cell infiltrate with numerous dilated blood vessels with extravasated red blood cells. Histological features were suggestive of infected dentigerous cyst.

Dentigerous cyst is an odontogenic cyst usually associated with unerupted teeth. Dentigerous cyst can be suspected when follicular space is more than 5 mm on radiographs [4]. Dentigerous cyst is usually asymptomatic and highest incidence of occurrence is in second and third decade of life. Radiographs may show unilocular or multilocular appearance [5]. Prevalance of achondroplasia is

approximately 1:15000. Dental features include delayed eruption of teeth, multiple impacted teeth, malocclusion and oligodontia [6]. In our case, patient exhibited oligodontia with multiple impacted supernumerary teeth with associated twin dentigerous cyst in mandibular arch, which is a very rare finding. The authors suggest that patients suffering from achondroplasia are susceptible to occurrence of dentigerous cysts especially when the patient has multiple impacted teeth. Further studies and case reports are required to know the exact relationship between achondroplasia and dentigerous cyst. Dentists and medical doctors should be mindful to thoroughly screen patients with achondroplasia at the earliest for possible occurrence of dentigerous cysts.

REFERENCES

- [1] Ireland PJ, Pacey V, Zankl A, Edwards P, Johnston LM, Savarirayan R. Optimal management of complications associated with achondroplasia. *Appl Clin Genet.* 2014;7:117-25.
- [2] Wang Y, Liu Z, Liu Z, Zhao H, Zhou X, Cui Y, et al. Advances in research on and diagnosis and treatment of achondroplasia in China. *Intractable Rare Dis Res.* 2013;2(2):45-50.
- [3] Singh M, Vijayanand, Siddalingappa MN, Sowmini. Achondroplasia and dentigerous cyst- a coincidental finding or any relationship? *J Clin Diagn Res.* 2015;9(5):ZL01-02.
- [4] Saluja JS, Ramakrishnan MJ, Vinit GB, Jaiswara C. Multiple dentigerous cysts in a nonsyndromic minor patient: Report of an unusual case. *Natl J Maxillofac Surg.* 2010;1(2):168-72.
- [5] Rohilla M, Namdev R, Dutta S. Dentigerous cyst containing multiple impacted teeth: a rare case report. *J Indian Soc Pedod Prev Dent.* 2011;29(3):244-47.
- [6] Kale L, Khambete N, Sodhi S, Kumar R. Achondroplasia with oligodontia: Report of a rare case. *J Oral Maxillofac Pathol.* 2013;17(3):451-54.

PARTICULARS OF CONTRIBUTORS:

1. Postgraduate Student, Department of Oral Medicine and Radiology, Yenepoya Dental College and Hospital, Yenepoya University, Mangalore, Karnataka, India.
2. Postgraduate Student, Department of Oral Medicine and Radiology, Yenepoya Dental College and Hospital, Yenepoya University, Mangalore, Karnataka, India.
3. Professor and Head, Department of Oral Medicine and Radiology, Yenepoya Dental College and Hospital, Yenepoya University, Mangalore, Karnataka, India.
4. Reader, Department of Oral Medicine and Radiology, Yenepoya Dental College and Hospital, Yenepoya University, Mangalore, Karnataka, India.
5. Professor, Department of Oral Medicine and Radiology, Yenepoya Dental College and Hospital, Yenepoya University, Mangalore, Karnataka, India.

NAME, ADDRESS, E-MAIL ID OF THE CORRESPONDING AUTHOR:

Dr. Vagish Kumar L Shanbhag,
Reader, Department of Oral Medicine and Radiology, Yenepoya Dental College and Hospital,
Yenepoya University, University Road, Deralakatte, Mangalore, Karnataka, India.
E-mail: vagishkumar_12@rediffmail.com

Date of Submission: **Apr 21, 2017**
Date of Peer Review: **Jun 14, 2017**
Date of Acceptance: **Jun 14, 2017**
Date of Publishing: **Jul 01, 2017**

FINANCIAL OR OTHER COMPETING INTERESTS: None.